

TIBIAL PLAFOND FRACTURES AND POSTEROLATERAL APPROACH IN SOUTHINDIANS

¹N.Shivananda Reddy *, ²T.G.Dinesh Krishna

¹Associate Professor, Department of Orthopaedics, Bharath Medical college and Hospital, Chennai (Affiliated to Bharath University, Chennai), India.

²Assistant Professor, Department of General Surgery, Bharath Medical college and Hospital, Chennai (Affiliated to Bharath University, Chennai), India

ABSTRACT

Open reduction and internal fixation of tibia plafond fractures have excellent results but also associated with increased risk of wound breakdown complications. Tibial plafond fractures have been approached through an anteromedial, anterolateral and posterolateral approach. Posterolateral approach carries few advantages than anteromedial approach like ability to fix both tibia and fibula through same approach, direct visualisation of posterior malleolus, lesser incidence of wound break down complications and better soft tissue coverage over implants. However this approach is limited to specific fracture pattern where comminution is predominantly posterior and has disadvantage of poor exposure to ankle joint compared to anteromedial approach. In our study of twenty patients of tibial plafond fracture with fibular fractures and fracture subluxation of ankle due to large posterior malleolar fragment, we used posterolateral approach we experienced stable fixation of both tibia and fibula and no wound complications.

Key words: Posterolateral, Plafond Fractures, Anteromedial.

INTRODUCTION

Posterolateral approach for open reduction and internal fixation of tibial plafond fractures has been better alternative to routine anteromedial approach. However, this approach demands specific fracture pattern in distal tibia [1-4]. This approach is recommended when comminution is located predominantly in posterior tibia along with fibular fractures and when anterior approach is not recommended because of condition of soft tissues. The advantages of this approach are lesser incidence of soft tissue complications and hence further infection and ability to fix both fibula and tibia through same incision and also less implant prominence as compared to routine anteromedial approach due to sufficient soft tissue coverage [5]. In this study of twenty patients we used posterolateral approach for open reduction and internal

fixation of tibial plafond fractures with fibula fractures and experienced excellent results.

Materials and Methods

In this study twenty patients who came to casualty of Bharath Medical college and Hospital, Chennai were admitted on emergency basis. Appropriate X-Rays were taken. All the patients had closed fractures. Patients were admitted and worked up for surgeries with proper pre-anaesthetic investigations. Patients were posted for surgeries on elective basis after making sure swelling had subsided. In one patient we applied external fixator spanning ankle due to extreme swelling on emergency basis. Proper consent was taken. CT scan was taken in all patients for adequate preoperative planning.

Results

Posterolateral approach to tibial plafond gave excellent reduction and stability in all twenty patients. One patient was applied with external fixator spanning ankle soon after trauma due to excessive swelling and internal soft tissue injury. Once swelling had subsided ,internal fixation with cortical screws and fibular plating was done through posterolateral approach. In other five patients

direct open reduction and internal fixation was performed. Fixation was stable in all patients with no intra articular step in distal tibia and proper fibular length was achieved. No wound complications were seen in any of the patients and no implant prominence were seen due to adequate soft tissue coverage. Clinioradiological union was seen in six months in four out of twenty patients.

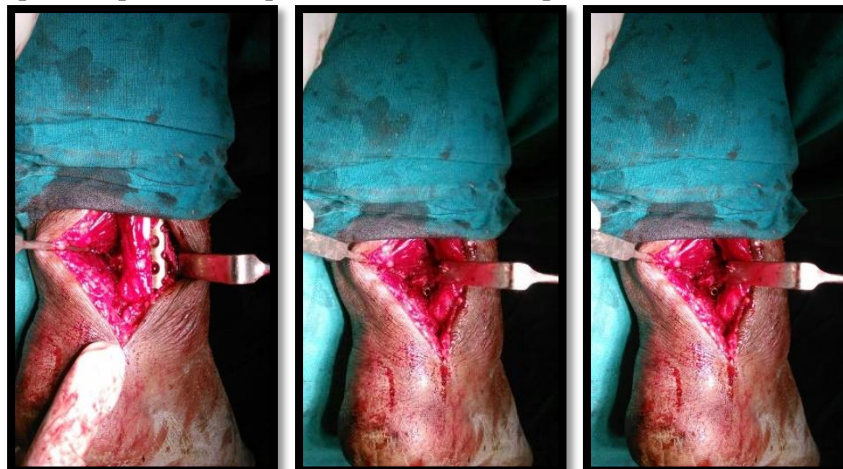
Figure 1. Showing pre op and post operative x rays of trimalleolar fracture fixed with recon plate and cancellous screw and K wire with IM nail situ. CT taken preoperatively also shown.

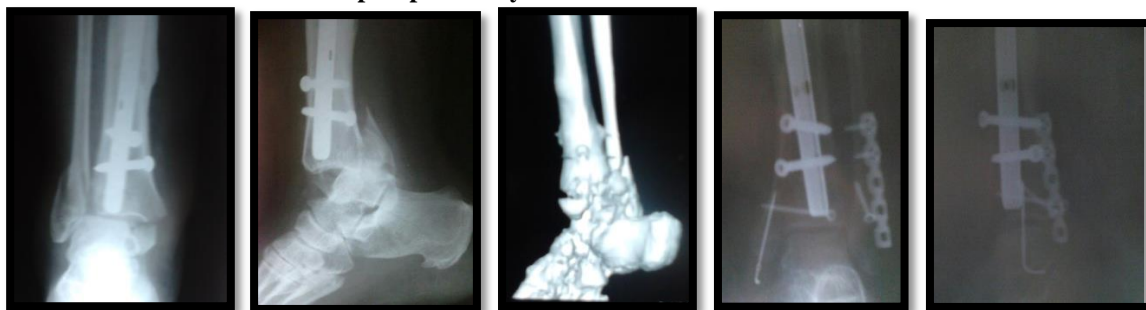

Figure 2 Showing pre operative and post operative X rays in case of trimalleolar fractures fixed with cancellous screws and one third tubular plate. Preoperative CT has also been shown.

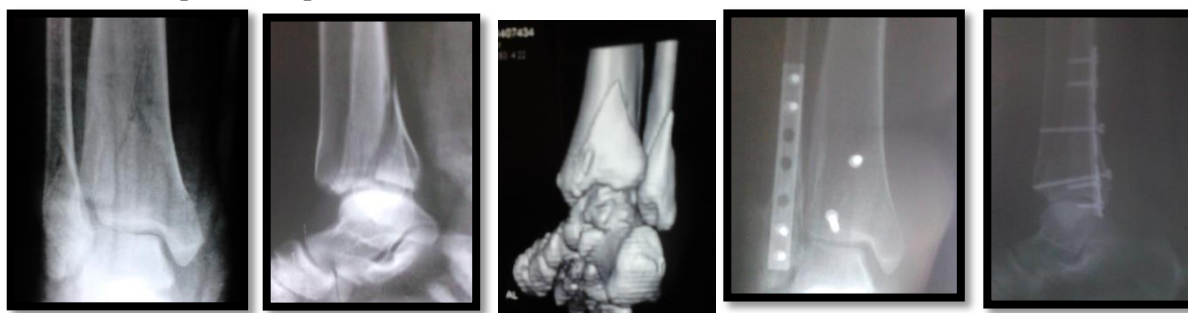

Figure 3 Showing intraoperative pictures in a patient fixed with recon plate and cancellous screws.



Discussion

Posterolateral approach to ankle have been proved to be better approach to tibial plafond fractures as compared to routine anteromedial approach. Benefits of posterolateral approach have been well documented in literature. The main advantage being

ability to approach both tibial and fibular fractures through same incision. This restricts need for two incision ,one for tibia anteromedially and one fibula laterally[6]. In all our patients in our study, we made incision along posterior border of fibula just lateral to achillis tendon[7]. The internervous plane being between flexor hallucis longus and peroneal tendon. We used

prone position in all patients. Sural nerve was identified and isolated in all patients[8]. In all patients fibula was fixed first with one-third tubular plate or recon plates[9]. In one patient, due to extreme comminution in fibula, we used tibial distractor spanning ankle. This method helped us in achieving fibular length. In one patient, due to low lateral malleolar fracture and oblique pattern, we used one-third tubular plate in antiglide mode[10]. In one patient, we used same approach with nail in situ which was put for tibial fracture and who developed trimalleolar fracture afresh.

Posterior malleolar component, in all patients were more than 25-30 % of the articular surface and hence decision for fixation was made[11]. Fragment was reduced through direct visualisation and was fixed with cannulated screws in all patients[12]. But disadvantage of this approach while reducing posterior malleolus being poor visualisation of ankle joint to know articular congruency. Hence we required c-arm guidance for reducing this fragment to check articular step. Due to this disadvantage of poor visualisation of ankle joint when compared to anteromedial approach, this approach demands particular fracture pattern. That is, this approach is suitable only when comminution is predominantly posterior and has restricted utility when comminution is anterior. In all our patients, fracture was predominantly posterior malleolus. In one patient there was associated medial malleolar fracture which was fixed with single K-wire by C-arm guidance[13].

The other advantage of this approach being lesser incidence of soft tissue complication and hence wound

breakdown complications. The reason being sufficient muscle cover to the plates by flexor hallucis longus. Due to this wound complications and hence risk of infection have been reported less with this kind of approach. Hence this approach is particularly useful in when skin and soft tissue condition is not favourable for anteromedial approach.

Due to the same reason of good muscle cover over plates, hardware prominence is less with this approach whereas hardware is easily felt in anteromedial approach. We did not come across wound complications in any of our operated patients. No patients had features of peroneal tenosynovitis[14].

All patients were given postoperative POPs and were immobilised for six weeks. In a patient with external fixator, fixator was removed after six weeks. All patients were started with range of movement exercises at six weeks. However weight bearing was restricted until twelve weeks.

Conclusion

The present study concludes that poster lateral approach to tibia plafond fractures is good alternative to the anteromedial approach when the fracture configuration allows to use this approach. It provides excellent exposure to posterior malleolus as well as fibula and allows to fix both through same approach under direct vision. The soft tissue coverage is better and hence wound complications are less. Hardware prominence is less too with this approach. Hence we recommend this approach in tibial plafond fractures involving posterior malleolus and lateral malleolar fractures.

REFERENCE:

1. Konrath, Gregory A .Posterolateral approach to tibial pilon fractures : a report of two cases. Journal of Orthopaedic Trauma.1999; 13: 586-589
1. 2.Jens Forberger, Philipp V Sabandal ,Michael Dietrich. Posterolateral approach to the displaced posterior malleolus: functional outcome and local morbidity.Foot and ankle international 2009; vol30:4309-314
2. Amr A.Abdelgawad , Adel Kadous. Posterolateral approach for treatment of posterior malleolus fracture of ankle. Journal of foot and Ankle surgery 2011;vol 50 issue 6:607-611
3. Jeong Hj, Kim KC, Chung SW,. Treatment of posterior malleolar fracture . J Korean Soc Frac 1998;11:924-931
4. Lee JY, Ha SH, Noh KH , Lee Sj . treatment of posterior malleolar fragment of trimalleolar fracture using posterolateral approach. J Korean Orthop Assoc 2009; 44:422-428
5. Talbot M , Steen Block TR, Cole PA. Posterolateral approach to open reduction and internal fixation of trimalleolar ankle fractures. Can J Surg 2005;48:487-490
6. Huang Ruo-kun , Xie Ming. Posterior malleolar fracture: technique and clinical experience of posterolateral approach . clinical journal of traumatology 2012; vo 15 no 1
7. Ellapparadja . safety profile of sural nerve in posterolateral approach to the ankle joint: MRI study. European journal of orthopaedic surgery and traumatology 2013
8. Daniel sheerin ; Clifford H Turen , Jason W. Reconstruction of distal tibia fractures using posterolateral approach and blade plate. Journal of orthopaedic trauma 2006;20(4):247-52
9. M. Huber , PM Stutz, C Gerber. Open reduction and internal fixation of posterior malleolus with posterior antiglide plate using posterolateral approach- preliminary report 1996; vol 2 issue 2:95-103
10. Mingo- Robinet , Abril Larrainzar. Postrolateral approach in trimalleolar ankle fractures :surgical technique. Europe pubmed central 2012; 56(4):313-318
11. Michael R. Carmont . buttress plate stabilisation of posterior malleolar fractures: a familiar technique through unfamiliar approach. Orthopaedics and trauma 2008; vol 22 issue 5 :359-64
12. Gwang Chu Lee, jun Young Lee, Sang Ho-ha. Treatment of trimalleolar fractures using posterolateral approach. Journal of Korean fracture society 2011;24(4):328-334
- 14.Schaffer JJ , Manoli A . The antiglide plate for distal fibular fixation . biomechanical comparison with fixation with lateral plate. J bone joint surgry 1987; 69: 596-604.