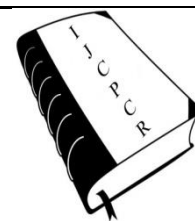




International Journal of Current Pharmaceutical & Clinical Research



www.ijcpcr.com

DIAGNOSIS OF APPENDICITIS WITH POST OPERATIVE HISTOPATHOLOGY OF LABORATORY FINDINGS IN INDIA

¹Geethanand K.V.S.S, ²Chekka Ramanujam, ³Pydi Maheswara Rao*

¹Associate Professor of General Surgery, Maharajahs Institute of Medical Sciences, Nellimarla, Andhra Pradesh 535217, India.

²Assistant Professor of General Surgery, Sardar Rajas Medical college and Hospital, Bhawanipatna, Odisha 766001, India.

³Associate Professor of General Surgery, NRI Institute of Medical Sciences, Andhra Pradesh 531163, India.

ABSTRACT

Unequivocal international guidelines regarding the diagnosis and management of patients with acute appendicitis are lacking. To determine the sensitivity and specificity of sonography in diagnosing acute appendicitis in patients with abdominal pain. All reports relating to appendicitis were retrospectively obtained from archived reports of our department and it is correlated with the histopathology reports. The accurate diagnosis of position of appendix & appendicitis is a combination of all the modalities and not just dependent on one basis in order to prevent post appendectomy complications and symptoms. The sensitivity, specificity, accuracy, positive and negative predictive values of sonography are comparable to statistics quoted in the literature. The most common error was the tendency to misclassify appendixes < 6 mm.

Key words: Appendicitis, Uncomplicated appendicitis, Complicated appendicitis, Appendectomy, Laparoscopic appendectomy.

of this study was to verify the accuracy of ultrasound imaging in the diagnosis of acute appendicitis with respect to intraoperative observations and the respective clinical and laboratory findings in young and in the elderly.

Acute appendicitis is the most common cause of acute abdomen in adolescents [1-4], frequent both in young and elderly, with an overall incidence of 7% as reported in the literature [5]. An important predictor in the clinical diagnosis of acute appendicitis is the classic migration of pain described by Murphy in 1905 [6]; according to the medical literature, this alone has a diagnostic accuracy of up to 95% [7,8]. The positivity of McBurney's sign increases suspicion of acute appendicitis [9]. If presentation is typical, the diagnosis of acute appendicitis

clinical and laboratory findings alone is not strong enough to diagnose acute inflammation of the appendix [11-16], and the use of a first-level diagnostic tool is essential for early diagnosis [17]. Aim of this study was to evaluate the diagnostic accuracy, sensitivity, and specificity of sonography in the evaluation of acute appendicitis in teaching hospital setting.

Materials and Methods Population:

We retrospectively analyzed our digitally archived sonography transcription reports. Using the presence of the keyword "appendicitis" in any section that is, Indication, Findings, or Impression—we identified 333 reports..

Corresponding Author :- **Dr. Pydi Maheswara Rao** Email:- drvrk@gmail.com

All these reports had at least a specific inquiry or a line in

the impression stating "no evidence of appendicitis" or

“consistent with appendicitis.” CT is not used primarily for workup of appendicitis at our hospital; instead, this technique is used as a problem-solving tool. Appendicitis is diagnosed either clinically or sonograms are obtained.

Sonography Technique:

All abdominal sonograms were obtained by radiologists with experience ranging from 2 to 15 years. Examinations were performed on an using both curved array 3- 5– MHz and linear array 7- 10– MHz transducers. All radiologists used the graded compression technique previously described by Puylaert [18]. Three criteria were generally used for the diagnosis of appendicitis: enlargement, lack of compressibility, and having a blind ending. An appendix was considered enlarged when the maximal cross-sectional diameter under compression was greater than 6 mm.

Follow-Up Procedures:

For patients who underwent appendectomy, the

sonography findings were compared with the microscopy report as the gold standard. Of the patients with false-positive findings on sonography, each specific sonography report was obtained and analyzed for the presence of the diagnostic criteria described earlier if the patients went to surgery. If the patient did not undergo surgery based on the surgeon's opinion, so any negative examination without surgery was interpreted as a true-negative .The outcomes of all 333 patients' reports were assessed.

Statistical Analysis:

The sensitivity, specificity, accuracy, positive predictive value, and negative predictive value of sonography in the detection of appendicitis were calculated. Subsets of sensitivity, specificity, and positive predictive value were also analyzed using age as a discriminator ($\leq 10, 11-18, \geq 19$ years). Statistical analyses were conducted using SPSS software-11.5 version. Variables were reported as mean \pm SD. P value of <0.05 was considered statistically significant.

RESULTS:

TABLE 1: Demographics of the Study Population

Parameter	Value
	No. of patients
Total	333
Male	122
Female	212
	Age (yrs)
Range	6–93
Mean	34

TABLE 2: Sensitivity, Specificity, Accuracy, and Positive and Negative Predictive Values of Sonography in Assessing Acute Appendicitis

Statistical Parameter	All Patients (n = 667)	Patient age (yrs)		
		≤ 10 (n = 42)	11–18 (n = 118)	≥ 19 (n = 507)
Sensitivity (%)	42	41	43	41
Specificity (%)	48	47	45	48
Accuracy (%)	46	45	44	42
Positive predictive value (%)	43	41	40	46
Negative predictive value (%)	47	47	47	47

TABLE 3: False-Positive Cases of Appendicitis by the Size of the Appendix

Size of Appendix (cm)	No. of Cases with False-Positive Sonography Findings
No size given	2
5	4
6	2
7	1
8	2
9+	1

TABLE 4 : Surgeon Self-Reported Positive Factors Most Likely to Affect Use of Sonography for Diagnosis of Acute Appendicitis

Factor	No of Cases		
	Mentioned	Most Important	Second Most Important

Paediatric patient	2	1	1
Equivocal clinical findings	1	1	1
No increased WBC	0	0	1
Time of day	2	0	0
Obesity	2	2	0

DISCUSSION:

Appendectomy is currently the surgical procedure most commonly performed by trainee surgeons. Etiologic mechanism of acute appendicitis appears to be multifactorial and seems to be caused by the combination of an ischemic event and a bacterial superinfection after luminal obstruction. The origins of surgical treatment of appendicitis date back a long way. The first open appendectomy was performed by McBurney in 1894 [19] and Kurt Semm performed the first laparoscopic appendectomy in 1983 [20].

A large set of appendiceal and periappendiceal criteria are used to diagnose acute ap pendicitis, with the most sensitive and specific being a diameter of 6 mm or greater (sensitivity, 98%; specificity, 98%), lack of compressibility (sensitivity, 96%; specificity, 98%), and inflammatory fat changes (sensitivity, 91%; specificity, 76%) [21].

The 100% specificity of the clinical examination refers to the ability of this procedure performed by an expert to correctly diagnose the condition. On the other hand, this type of examination has a sensitivity of 67.9% in that, especially in female patients, it is less accurate in distinguishing between right acute abdomen and gynecological disorders. Laboratory findings do not achieve the specificity of clinical examinations, as they only give a general measure of the inflammation but are never specific. Ultrasound has a specificity of 50%, due to the fact that the appendix is not always visible, even in patients with acute appendicitis; however, sensitivity is high as this type of investigation is able to evaluate the consequences of inflammatory events with extreme accuracy.

Seven of the 23 false- positives in our study had an appendix diameter of 5 mm, making it the most common error in cases of misdiagnosis A non visualized appendix also presents a major diagnostic difficulty because one can not confidently exclude appendicitis without examining the appendix. Negative predictive values were low for all methods. All produced a small number of true negatives and a large number of false negatives. The false negative results produced by laboratory investigations can be accounted for by the non specific nature of inflammatory values and the fixed lower limit of our scale. False negative clinical diagnoses referred to patients in whom the findings of the clinical

examination were not fully in agreement with the classification and whose abdominal symptoms were less clear and non specific. Positive predictive values were high for all methods: the 100% for physical examinations was due to the negative nature of the false positive diagnoses these produced. The high positive predictive values of laboratory findings and ultrasound were also due to the small number of false positives produced. The five false positive diagnoses produced by ultrasound imaging were attributable to the identification of two minor diagnostic factors, namely pelvic effusion and periappendiceal lymphadenopathy, which are not specific to acute appendicitis. The four false positive diagnoses produced by laboratory findings were due to the non specific nature of high inflammatory marker levels.

An important limitation of sonography in the examination of patients with perforated appendix is its lower sensitivity compared with nonperforated cases [22]. CT would be the preferred imaging method in this case; however, at our institution, CT for appendicitis is used only as a problem- solving tool because we have only one CT scanner.

CONCLUSION:

The sensitivity, specificity, accuracy, and positive and negative predictive values of sonography performed by radiologists in a teaching hospital are comparable to statistics quoted in the literature. The most common error was the tendency to misclassify appendixes less than 6 mm as appendicitis.

Appendicitis is a very common surgical entity with a wide of complications and post appendicectomy symptoms. The accurate diagnosis of appendicitis still remains a challenge for the surgeon and the rate of negative appendicectomy with post appendicectomy symptoms are increasing due to inaccurate diagnosis. In our study we used a total of five modalities for the diagnosis of position of appendix & appendicitis, i.e. clinical features, lab Ix, ultrasound, intraoperative findings & histopathology, there is number of cases all the modalities were positive. So the accurate diagnosis of position of appendix & appendicitis is a combination of all the modalities and not just dependent on one basis in order to prevent post appendicectomy complications and symptoms.

REFERENCE:

1. Ronan P, Connell O , *et al.* The vermiform appendix, in: R.C. Russell, N.S. Williams, C.J. Bulstrode (Eds.), Bailey and Love's Short Practice of Surgery, twenty-third ed., *Arnold Publishers, London*, 2000, 1076e1092.
2. Kozar R.A., Roslyn J.J, *et al.* The appendix, in: S.I. Schwartz (Ed.), Principles of Surgery, 7th International ed., McGraw-Hill Health Profession Division, 1999, 1383e1094.

3. Condon R.E, Appendicitis, in: D.C. Sabiston (Ed.), Textbook of Surgery, thirteenth ed., W B Saunders, Philadelphia, 1986, 967e982.
4. Addiss D.G, Shaffer N, Fowler B.S, Tauxe, *et al.* The epidemiology of appendicitis and appendectomy in the United States, *Am. J. Epidemiol.* 132 (1990), 910e925.
5. Liu C.D, McFadden D.W, in: L.J. Greenfield (Ed.), *et al.* Acute Abdomen and Appendix.Surgery: Scientific Principles and Practice, Lippincott-Raven, Philadelphia, 1997, 1246e1261.
6. Murphy J.B, *et al.* Appendicitis with original report, histories, and analysis of 141 laparotomies for that disease, *JAMA* 22 (1894), 302e308.
7. Paulson E.K, Kalady M.F, Pappas T.N, *et al.* Clinical practice. Suspect appendicitis, *N. Engl. J. Med.* 348(2003), 236e242.
8. Birnbaum B.A, Wilson S.R, *et al.* Appendicitis at the millennium, *Radiology* 215(2000), 337e348.
9. Yeh B, Evidence-based emergency medicine/rational clinical examination abstract. Does this adult patient have appendicitis? *Ann. Emerg. Med.* 52(2008), 301e303.
10. Sivit C.J, Newman K.D, Boening D.A, *et al.* Appendicitis: usefulness of US in diagnosis in a pediatric population, *Radiology*, 185(1992), 549e552.
11. Lam_iris W, Van Randen A, Go P.M, *et al.* Single and combined diagnostic value of clinical features and laboratory tests in acute appendicitis, *Acad.Emerg. Med.* 16(2009), 835e842.
12. Cardall T, Glasser J, Guss D.A, *et al.* Clinical value of the total white blood cell count and temperature in the evaluation of patients with suspected appendicitis, *Acad. Emerg. Med.* 11(2004), 1021e1027.
13. Wagner J.W, McKinney W.P, Carpenter J.L, Does this patient have appendicitis? *JAMA* 276(1996), 1589e1594.
14. Amalesh T, Shankar M, Shankar R, *et al.* CRP in acute appendicitis is it a necessary investigation? *Int. J. Surg.* 2, (2004) 88e89.
15. Johansson E.P, Rydh A, Riklund K.A, *et al.* Ultrasound, computed tomography, and laboratory findings in the diagnosis of appendicitis, *Acta Radiol.* 48(2007), 267e273.
16. Kessler N, Cyteval C, Gallix B, *et al.*, Appendicitis: evaluation of sensitivity, specificity, and predictive values of US, Doppler US, and laboratory findings, *Radiology* 230 (2004), 472e478.
17. Wilcox R.T, Traverso L.W, Have the evaluation and treatment of acuteappendicitis changed with new technology? *Surg. Clin. North Am.* 77 (1997) 1355e1370.
18. Puylaert JB, *et al.* Acute appendicitis: US evaluation using graded compression. *Radiology* 158, 1986, 355–360.
19. McBurney C, The incision made in the abdominal wall in cases of appendicitis,with a description of a new method of operating, *Ann. Surg.* 20(1894), 38e43.
20. Semm K, Endoscopic appendectomy, *Endoscopy* 15(1983), 59e64.
21. Kessler N, Cyteval C, Gallix B, *et al.* Appendici- tis: evaluation of sensitivity, specificity,and pre- dictive values of US, Doppler US, and laboratory findings. *Radiology* 2004, 230, 472–478.
22. Borushok KF, Jeffrey RB , Laing FC, Townsend RR, *et al.* Sonographic diagnosis of perforation in patientswith acute appendicitis. *AJR* 154, 1990, 275–278.