



WHAT ARE THE RISKS OF LEPTOSPIROSIS TRANSMISSION FROM CULTURES TO LABORATORY WORKERS? - A CASE REPORT

Prabhusaran Nagarajan^{1*}, Jeyaseelan Senthinath², Natarajaseenivasan Kalimuthusamy³, Joseph Pushpa Innocent Danialas⁴

¹Postgraduate and Research Department of Microbiology, Chennai Medical College Hospital and Research Centre (SRM Group), Tiruchirapalli, INDIA and D.Sc. Research Scholar in Microbiology, The Tamilnadu Dr. M.G.R. Medical University, Chennai, Tamilnadu, India.

²Department of Microbiology, Ponniah Ramajayam Institute of Medical Sciences, Kancheepuram, Tamilnadu, India.

³Department of Microbiology, School of Life Sciences, Bharathidasan University, Tiruchirapalli, Tamilnadu, India.

⁴Department of Microbiology, Karpaga Vinayaga Institute of Medical Sciences, Kancheepuram, Tamilnadu, India.

ABSTRACT

Handling the leptospiral cultures in the clinical and research laboratories often creates anxiety among technical staff members and scientists that fear autologous infections accidentally. The leptospiral cultures have to be maintained and subcultured in a highly technical manner and the culture medium is more sensitive to get contamination. In some cases, the cultures accidentally exposed to the handlers by inoculation of by ingestion. Here we are presenting a case for creating awareness to all healthcare workers who are handling leptospiral cultures. According to us usage of proper personal protective equipments and standard post handling disinfection should be sufficient to prevent transmission to handlers. Therefore, prevention of anxiety and handling the cultures with proper preventive measures should be followed.

Key words: Healthcare workers, Prevention, PPEs, Leptospirosis transmission.

INTRODUCTION

Any employee who is exposed to infectious biological agents on the workplace is prone to get (primary) infections and that are collectively called as laboratory acquired infections (LAIs) [1]. In the laboratory, an infection can occur via cutting injuries, accidental injection or inoculation and through contact of the mucous membranes. While processing the live microbial pathogens, the accidental exposure and inoculation leads to infection is occurred [2-4].

In the laboratory, an infection can occur via cutting injuries and through contact of the mucous membranes with aerosols that contain high titres of the virus. Another example is the handling of bacterial pathogens such as *Leptospira interrogans*. This bacterial pathogen is usually transmitted by animals (rodents) [5]. In

a (research) lab however, a lab worker could become infected by needle stick injury or exposure of the mucous membranes of the eyes, nose or mouth [6, 7].

Leptospirosis is a zoonotic disease mainly spread by rodents especially rats. The urine of the animals is a potent substance that harbours leptospire. Most of the time, this disease is described as occupational hazard that ranges the clinical features from mild pyrexia to multiorgan failure. In most of the situations, patients are easily recovered from the infection by early diagnosis and proper antibiotic therapy [8].

Various occupational groups pose risk of getting infections while handling or exposing to pathogens. Veterinarians, animal slaughter house workers and laboratory workers who are exposed with animal carriers

and live leptospire are referred as high risk groups [9] and while handling leptospiral cultures have been reported [10]; thus leptospirosis is considered as one of the commonest laboratory acquired infections [11]. In continuation of this literature, a case was described here with leptospiral culture and seroprints in the laboratory worker cum researcher who continuously exposing to leptospiral cultures for the past 15 years.

CASE STUDY

A 35 year old male scientist cum laboratory worker opened the screw capped leptospiral cultures in the laboratory for doing subculturing. It was noticed that the tube was already cracked and the lid was very tight. He forced the tube and opened. The tube broke and the glass piece tarred the glove in the right hand and also a small cut was observed. Immediately the broken tube was discarded aseptically and spilled cultures were cleaned by surface filling with hydrogen peroxide and sodium hypochlorite.

After 10 minutes of cleaning the environment and discarded the broken tubes, the laboratory worker cleaned his fingers with soap and exposed the wound to running tap water. The culture spilled and broken was noted as Grippotyphosa, a culture obtained from National leptospirosis reference centre, Regional Medical Research Centre, Portblair, Andaman and Nicobar islands. This culture was obtained from the reference centre on August 2014 and subcultured every 15 days in EMJH semisolid medium (Himedia) with necessary supplements [12].

After 15 days of this accidental incident, he developed fever and headache; where he was given with oral doxycycline and advised him to consume more water to avoid the renal abnormalities induced by the drug. Meanwhile blood sample was collected and two drops of blood was inoculated on EMJH semisolid medium without 5-fluorouracil. Serology was also performed by following the standard protocol of genus specific IgM ELISA as per the instructions of the manufacturer and serovar specific Microscopic agglutination test (MAT).

The MAT was performed using twelve leptospiral serovars as antigens obtained from reference centre [*Leptospira interrogans* serogroup Australis (serovar

Australis and strain Ballico); serogroup Autumnalis (serovar Bangkinang and strain Bangkinang 1); serogroup Canicola (serovar Canicola and strain H. Uterrecht IV); serogroup Grippotyphosa (serovar Grippotyphosa and strain Moskva V); serogroup Hebdomadis (serovar Hebdomadis and strain Hebdomadis); serogroup Icterohaemorrhagiae (serovar Icterohaemorrhagiae and strain RGA); serogroup Javanica (serovar Poi and strain Poi); serogroup Pomona (serovar Pomona and strain Pomona); serogroup Semeranga (serovar Patoc and strain Patoc 1); serogroup Sejroe (serovar Sejroe and strain M84); serogroup Sejroe (serovar Hardjo and strain Hardjoprajtno) and serogroup Pyrogens (serovar Robinsoni and strain Robinson)] and the protocol was followed as standard described [7,13].

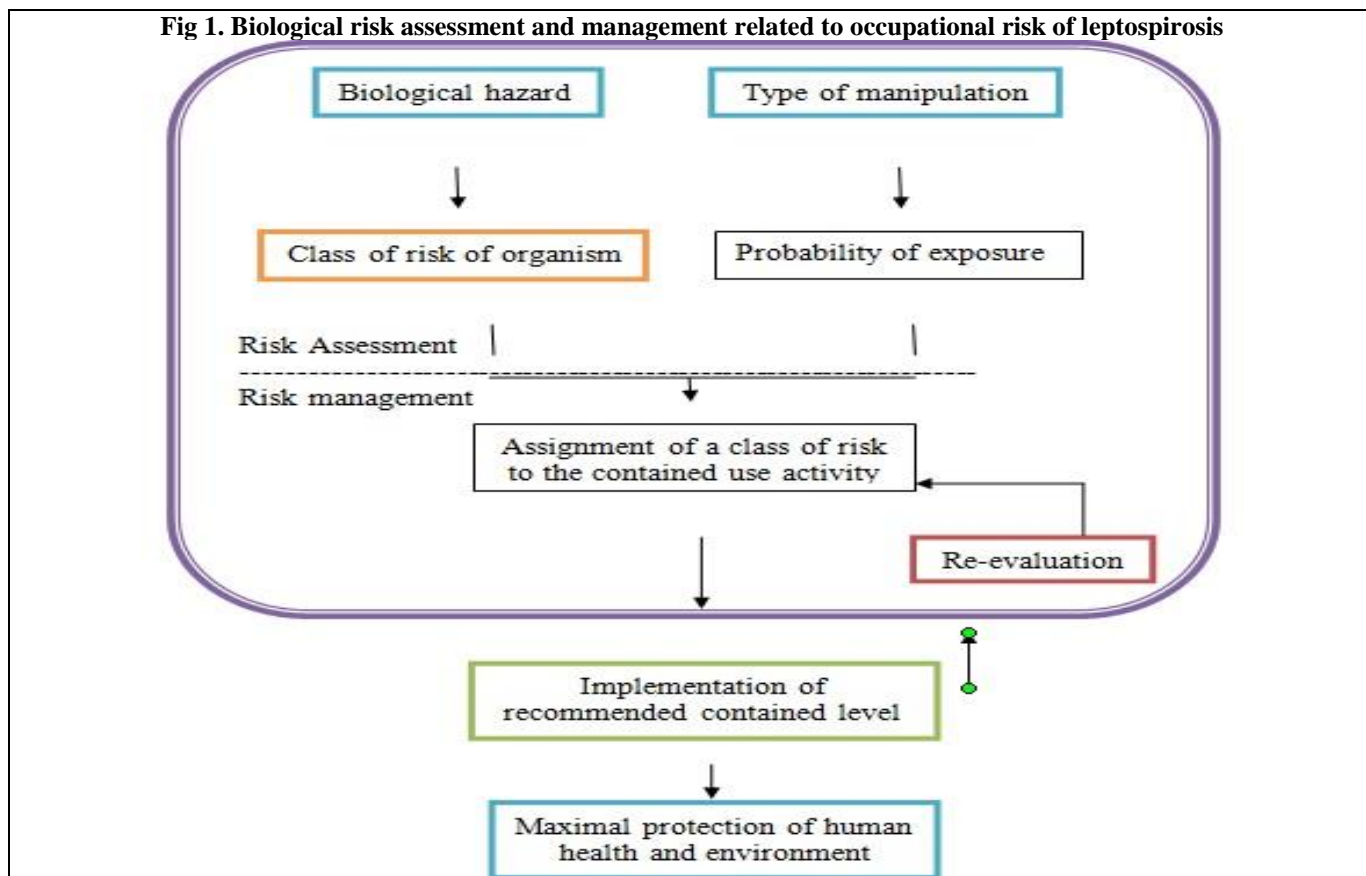
The laboratory finding suspected with leptospirosis showed negative in serology in acute and immediate serum sample but later after 15 days of incident showed positive to both ELISA and MAT. The ELISA was reactive and MAT showed highest titre of 1:320 against serovar Grippotyphosa, 1:160 against Australis and 1:80 against Autumnalis and this may due to contamination of the cultures. Biochemically liver function test (LFT) and renal function test (RFT) were normal. Thrombocytopenia observed with the count of below 75,000/ sq.mm. The leptospiral culture was also supported the serovar Grippotyphosa and it was confirmed by the reference centre using Cross agglutination absorption test (CAAT). The overview related to the leptospirosis investigations in the case (laboratory worker) recorded was depicted in table 1.

Further the fever not residing and nausea observed. No record of vomiting. Later he was admitted and doxycycline was administered intravenously for three days with ciprofloxacin. He recovered and advised to continue the antibiotic treatment orally for 7 days. A convalescent sample (blood) was collected after symptoms resided showed negative to direct dark field microscopy and serology lowered in titre determination by MAT. From this study it was clearly noted that administration of intravenous doxycycline may support the patients.

Table 1. Laboratory report (specific to leptospirosis)

Sample	Phase	DDFM	Culture	ELISA	MAT	Titre	Serovar
Blood (Serum)	Acute (Day 1 of incident)	Negative	Negative	Non reactive	Non reactive	-	-
	Convelescent sample (Day 1 of symptoms)	Positive	Positive (Grippotyphosa)	Reactive	Reactive	1:320	Grippotyphosa
						1:160	Australis
						1:80	Autumnalis
Sample after recovery	Negative	Negative	Reactive with low titre value				

Fig 1. Biological risk assessment and management related to occupational risk of leptospirosis



DISCUSSION AND CONCLUSION

In some instances, the laboratory acquired leptospirosis was documented [6, 9-11], no such reports documents later in any journals and clinical records. Newer observations will be documented in future and may be helpful for the clinicians to suspect leptospirosis while taking clinical history. From this study it was clearly depicted the following important notifications for the Clinical Microbiologists, Pathologists and Clinical practitioners.

- Spotlight on the virulence of laboratory leptospiral strains [6]
- Understanding the incubation period
- Effectiveness of antibiotics (doxycycline and ciprofloxacin)
- Usefulness of early laboratory investigations [8]
- Analysing the biochemical (LFT and RFT) tests and determination of thrombocytopenia [14]

Even though standard personal protective equipments were used during the laboratory practices, accidental infection of leptospirosis is occurred. It is found rare and most of the time not recorded. The major reason of this case description was due to the exposure of the subject to the cracked, broken and tightly screwed lid in the laboratory. The validity of the screw capped tubes were determined by it's maintenance. Some literature suggested

the culture tubes were washed with cleaning fluid (10% potassium dichromate, 15% sulphuric acid and 75% distilled water) and further dried and sterilized in a hot air oven [6]. In our laboratory, we standardized the cleaning solution as 10% potassium dichromate, 15% sodium hypochlorite, 15% hydrogen peroxide and 60% water.

The immediate reporting to medical personnel is mandatory after exposed to leptospiral cultures accidentally, because of that only the person was recovered earlier using appropriate antibiotics. The early and prompt diagnosis also supported the patient to recover earlier. During clinical examination it was found that the patient developed the symptoms (headache and fever) after 15 days of incident. This is interesting to note as the incubation period of leptospirosis ranges from 2 to 20 days and often it is between 5 and 14 days [6,15].

This is further clearly depicted that the leptospiral cultures were highly virulent even after 22 passages in EMJH semisolid medium. Previous study suggested that the pathogenicity of *L. australis* was retained even after 52 passages [6]. The possibility of recovering isolates from blood culture was observed within 20 days whereas previous report highlighted recovery was possible after 2 months incubation [6]. In most cases, the leptospiral isolates could have been missed if the tubes were discarded after 3 weeks incubation. The percutaneous exposure of

leptospirosis infection is also possible and defined as high risk while handling cultures.

During 1960 to 1976, 3 laboratory acquired infections (LAIs) due to leptospirosis were reported [11] and one case was recorded in 2003 [6]. Therefore, the laboratory workers who handling live leptospiral cultures for MAT and other techniques should be followed the standard risk assessment and management as described in figure 1. The regular screening of laboratory workers should also performed to understand the transmission pattern of the infectious entity.

For the risk assessment and management of leptospiral infection in the laboratory, the five successive steps are useful.

1. Identification of biological hazard
2. Determination of the class of risk of the pathogenic organism
3. Consideration of the type of activity in terms of probability of exposure to potential biological hazard

4. Assignment of a class of risk to the contained use activity
5. Implementation of recommended containment level (risk management)

ACKNOWLEDGEMENT: None

CONFLICT OF INTEREST:

The authors declare that they have no conflict of interest.

STATEMENT OF HUMAN AND ANIMAL RIGHTS:

All procedures performed in human participants were in accordance with the ethical standards of the institutional research committee and with the 1964 Helsinki declaration and its later amendments or comparable ethical standards. This article does not contain any studies with animals performed by any of the authors.

REFERENCES

1. Sewell DL. Laboratory-acquired Infections. *Clinical Microbiology Newsletter*, 22, 2000, 73-77.
2. Singh K. Laboratory-acquired infections. *Clinical Infectious Diseases*. 49, 2009, 142-147.
3. Baron EJ, Miller MM. Bacterial and fungal infections among diagnostic laboratory workers: evaluating the risks. *Diagnostic Microbiology and Infectious Disease*, 2008, 60, 241-6.
4. Droogenbroeck C, Beeckman DS, Verminnen K, Marien M, Nauwynck H, Boesinghe LT. Simultaneous zoonotic transmission of *Chlamydia psittaci* genotypes D, F and E/B to a veterinary scientist. *Vet Microbiol*, 2009, 135, 78-81.
5. Prabhu N, Natarajaseenivasan K, Joseph PID. Survey of leptospiral pathogens carried by rodents at different areas of Tiruchirapalli, India. *Int J Ext Res*, 2015, 6, 26-31.
6. Sugunan AP, Natarajaseenivasan K, Vijayachari P, Sehgal SC. Percutaneous exposure resulting in laboratory-acquired leptospirosis – a case report. *J Med Microbiol*, 2004, 53, 1259-62.
7. Natarajaseenivasan K, Prabhu N, Selvanayagi K, Raja SSS, Ratnam S. Human leptospirosis in Erode, South India: serology, isolation and characterization of the isolates by randomly amplified polymorphic DNA (RAPD) fingerprinting. *Jpn J Infect Dis*, 2004, 57, 193-197.
8. Prabhu N, Natarajaseenivasan K, Joseph PID. Importance of serological analysis – an interpreter of identifying infecting serovar in patients with leptospirosis. *Med Sci*, 2014, 8, 27-31.
9. Campagnolo ER, Warwick MC, Marx HL. Analysis of the 1998 outbreak of leptospirosis in Missouri in humans exposed to infected swine. *J Am Vet Med Assoc*, 2000, 216, 676-682.
10. Gilks CF, Lambert HP, Broughton ES & Baker CC. Failure of penicillin prophylaxis in laboratory acquired leptospirosis. *Postgrad Med J*, 1988, 64, 236-238.
11. Sullivan JF, Songer JR & Estrem IE. Laboratory-acquired infections at the National Animal Disease Center 1960-1976. *Health Lab Sci*, 1978, 15, 58-64.
12. Prabhusaran N, Natarajaseenivasan K, Joseph PID. Appearance of black pigment in the EMJH semisolid medium – cultural confusion. *Eur J Pharmaceu Med Res*, 2015b, 2, 864-872.
13. Wolff JW. Serological procedures. In *Laboratory Diagnosis of Leptospirosis*, 1959, 39-62.
14. Prabhu N, Joseph PID, Chinnaswamy P. Thrombocytopenia in leptospirosis and role of oral amoxycyline and doxycycline in patient management. *Int J Pharmceu Sci Biotechnol*, 2010, 1, 25-29.
15. Turner LH. Leptospirosis. *Trans R Soc Trop Med Hyg*, 1967, 61, 842-854.