



## A COMPARISON OF MRI AND COMPUTED TOMOGRAPHY IMAGING TECHNOLOGY AND FURTHER ADVANCES

Nagavarapu Suneetha<sup>1\*</sup>, Udhayan Felix<sup>2</sup>

<sup>1</sup>Associate Professor of Radiology, Sathya Sai medical college, Tamilnadu, India.

<sup>2</sup>Associate Professor of Radiology, Melmaruvathur Adhiparasakthi Institute of Medical Sciences, Melmaruvathur, Tamilnadu, India.

### ABSTRACT

Computed tomography (CT) is an essential tool in diagnostic imaging for evaluating many clinical conditions. In recent years, there have been several notable advances in CT technology that already have had or are expected to have a significant clinical impact, including extreme multidetector CT, iterative reconstruction algorithms, dual-energy CT, cone-beam CT, portable CT, and phase-contrast CT. These techniques and their clinical applications are reviewed and illustrated in this article. In addition, emerging technologies that address deficiencies in these modalities are discussed. Magnetic Resonance Imaging (MRI) has been a potential tool in diagnostics in lesions in human body. It is accurate due to the sound biological principle behind it. It has an array of unique features; but is not free from certain constraints which hinder the smooth progression of its course. This article throws light on the salient features and constraints pertaining to MRI, with an insight towards the future prospects of the same.

**Key words:** Iterative Reconstruction, Dual-Energy Ct, Cone-Beam Ct, Portable Ct, Phase-Contrast Ct, Magnetic Resonance Imaging, Dentistry

### INTRODUCTION

MRI (Magnetic Resonance Imaging) is a non-invasive method of mapping the internal structure and certain aspects of function within the body. It uses non-ionizing electromagnetic radiation and appears to be without exposure-related hazard. It employs radio frequency (RF) radiation in the presence of carefully controlled magnetic fields in order to produce high quality cross-sectional images of the body in any plane. The MR Image is constructed by placing the patient inside a large magnet, which induces a relatively strong External magnetic field. This causes the nuclei of many atoms in the body, including Hydrogen, to align them with the magnetic field and later application of RF signal, Energy is released from the body, detected and used to construct the MR image by Computer.(1)

The MR system comprises two main groups of equipment. The first is the control centre, which

is positioned where the operator sits. The control centre houses the 'host' computer with its graphical user interface. Its associated electronics and power amplifiers are usually situated in an adjacent room and connect to the second equipment group. This second group of equipment is housed within the machine in which the patient lies. It contains the parts of the MR system that

Generate and receive the MR signal and include a set of main magnet coils, three gradient coils, shim coils and an integral radiofrequency (RF) transmitter coil. (2) The MR system uses a set coordinates to define the direction of the magnetic field. Gradient coils representing the three orthogonal directions (x, y and z) lie concentric to each other within the main magnet (Fig 1).

Corresponding Author :- **Dr.Nagavarapu Suneetha**, Email:- nithish@gmail.com

They are not supercooled and operate relatively close to room temperature. Each gradient coil is capable of generating a magnetic field in the same direction as B<sub>0</sub>, but with a strength that changes with position along the x, y or z directions, depending on which gradient coil is used.

### Historical Aspects:

1857-1952 :Larmor relationship –Sir Joseph Larmor: The rate of frequency of precession of proton is termed Larmor frequency. (3) 1930 : Isidor Isaac Rabi succeeded in detecting single state of rotation of atoms and molecules, and in determining the mechanical and magnetic moments of the nuclei. (4) 1946 : MR phenomenon – Bloch and Purcell (5) 1952 : Nobel Prize – Bloch and Purcell (6) 1950-70 : Nuclear Magnetic Resonance imaging developed as analytical tool. (3) 1972 : Computerized Tomography was introduced. (3) 1973 : Back projection MRI – Lauterbur. (3) 1975 : Fourier Imaging – Erust (3) 1977 : Echo-planar imaging – Mansfield (7) 1980 : FT MRI demonstrated – Edelstein (3) 1986 : Gradient Echo Imaging: NMR Microscope (8) 1987 : MR Angiography- Dumoulin.(3) 1991 : Nobel Prize – Ernst. (9) 1992 : Functional MRI (3) 1994 : Hyperpolarized 129 Xe Imaging. (3) 2003 : Nobel Prize :Lauterbur and Mansfield for contributions in MRI. (3)

### Salient Features:

1. No Ionizing Radiation: RF pulses used in MRI do not cause ionization and have no harmful effects of ionizing radiation. Hence can be used in child bearing ladies and children. 2. Non-invasive: MRI is non-invasive.3. Contrast resolution: It is the Principle advantage of MRI, i.e. ability of an image process to distinguish adjacent soft tissue from one another. It can manipulate the contrast between different tissues by altering the pattern of RF pulses. 4. Multiplanar image: With MRI, we can obtain direct, sagittal, coronal and oblique image which is impossible with radiography and CT.5. It could differentiate between acute and chronic transit and fibrous phases parallel with histopathological changes.6. Absence of significant artifact associated with dental filling.7. No adverse effect has yet been demonstrated.8. Image manipulation can be done. 9. Useful in determining intramedullary spread.

### Applications in Dentistry:

#### Signal intensity for each tissue:

**1. Fat tissues:** Fat tissue appears as high signal intensity on T1 Weighted images and low signal intensity on T2-Weighted images with fat suppression

#### 2. Muscle tissue:

Muscle commonly appears as low signal intensity on both T1 and T2-weighted images with fat suppression except Lingual muscles, which have intermediate signal

intensity on T1-weighted images due to their relatively high fat component compared to other muscles.

#### 3. Cortical bone tissue:

Cortical bone tissue is indicated as a signal intensity void on T1 and T2-weighted images. Cancellous bone tissue demonstrates high intensity on T1-weighted images and low intensity on T2-weighted images with fat suppression.

#### 4. Lymph nodes and tonsils:

Lymph nodes and tonsils have low intensity on T1-Weighted images and intermediate –high signal intensity on T2-Weighted images with fat suppression.

#### 5. Teeth:

The teeth, except pulp tissue, appear as a signal void on T1 and T2-weighted images; pulp tissue has intermediate signal intensity on T1 –Weighted images and high signal intensity on T2 weighted images with fat suppression. The dental follicle of an unerupted tooth has signal intensity on T1-weighted images and high signal intensity on T2-weighted images with fat suppression.

#### 6. Parotid gland:

Signal intensities differ among the tissues of the salivary glands. The parotid glands have relatively high signal intensity on T1-weighted images and low signal intensity on T2- weighted images with fat suppression. While the parotid ducts have high signal intensity on T2-weighted images with fat suppression and low signal intensity on T1-weighted images.

#### 7. Submandibular gland:

The submandibular glands have intermediate signal intensity on T1 –weighted images and low signal intensity on T2-weighted images with fat suppression. Ducts have high signal intensity on T2-weighted images with fat suppression and low signal intensity on T1-weighted images.

#### 8. Sublingual gland:

The sublingual gland has intermediate signal intensity on T1–weighted images and high signal intensity on T2- weighted images with fat suppression.

#### 9. Temporomandibular Joint (TMJ):

Mandibular Joint (TMJ): The discs of the TMJ have low signal intensity on T1 and T2-weighted images. TMJ effusion appears as low signal intensity on T1-weighted images and high signal intensity on T2-weighted images.

#### 10. Cavities:

The cavities (maxillary sinus and nasal cavities) appear as void signal on T1 and T2-weighted images.

### 11. Blood vessels:

Blood vessels usually have void signal intensity due to blood flow, termed „signal void“, on both T1 and T2 –weighted images, however, some vessels with lower flow rate appear with high signal intensity on T2-weighted images with fat suppression and low intensity on T1-weighted images, like the signal from water. (2,10)

#### Indications of MRI in the oral and maxillofacial region

- a) For the diagnosis and evaluation of benign and malignant tumors of jaws.
- b) Tumor staging evaluation of the site, size and extent of all soft tissue tumors and tumor like lesions, involving all areas including.Ÿ The salivary glands,Ÿ The pharynx,Ÿ The Sinuses,Ÿ The orbits.
- c) To evaluate structural integrity of trigeminal nerve in trigeminal neuralgia.
- d) In surgery of parotid gland MRI can detect the cause of facial nerve within the glandular tissue and help lessen the likelihood of postoperative facial nerve palsy.
- e) For the assessment of intracranial lesions involving particular posterior cranial fossa, the pituitary and the spinal cord.
- f) For non-invasive evaluation of the integrity and position of articular disk with in the TMJ.
- g) Investigation of the TMJ to show both the bony and soft tissue components of joint including disc position:
  - a. When diagnosis of internal derangement is in doubt,
  - b. As a preoperative assessment before disc surgery,
  - c. Implant assessment. (2, 10)

#### Limitations:

- Claustrophobia i.e. morbid fear of closed places because the patient is within the large magnet up to one hour.
- 2. MRI equipment is expensive to purchase, maintain, and operate. Hardware and software are still being developed.
- 3. Because of the strong magnetic field used in patient electrically, magnetically or mechanically activated implants such as cardiac pacemakers, implantable defibrillators and some artificial heart valves may not be able to have MRI safely.
- The MRI image becomes distorted by metal, so the image is distorted in patients with surgical clips or stents, for instance.
- Bone does not give MR signal, a signal is obtained only from the bone marrow. Long scanning time and requires patient cooperation.
- The very powerful magnets can pose problems with sitting of equipment although shielding is now becoming more sophisticated.
- MRI scanners are noisy.

- Patient could develop an allergic reaction to the contrasting agent, or that a skin infection could develop at the site of injection.
- MRI cannot always distinguish between malignant tumors or benign disease, which could lead to a false positive result.
- Facilities are not widely available, but with the development of small open systems suitable for district general hospitals.
- Bone, teeth, air and metallic objects all appear black, making differentiation difficult.

#### Recent Advances:

##### 1) Volume imaging – 3D imaging:

Volume imaging is the requisition of magnetic resonance data from a volume rather than a tomographic slice. It can be thought of as collecting several contiguous slices through a region of imaged object.

##### 2) Flow imaging (MRI angiography MRA):

Angiography is the imaging of flowing blood in the arteries and veins of the body. MRA produces images of flowing blood. The intensity in these images is proportional to the velocity of the flow. There are 3 general types of MRA – time of flight, phase contrast angiography and contrast enhanced angiography.

**3) Fast spin: Echo imaging is a multi-echo spin echo sequence** where diff parts of space are recorded by different spin echoes. The benefit of the technique is that a complete image can be recorded in 1/4th of the time.

##### 4) Chemical shift imaging (fat suppression):

Is the production of an image from just one chemical shift component in a sample.

##### 5) Echoplanar imaging (functional MRI) (fMRI):

Is a rapid MRI technique which is capable of producing tomographic images at video rates. Its greatest application appears to be in the area of functional MRI of the brain. Functional imaging is the imaging which relates body function or thought to specific locations in the brain.

##### 6) Magnetization transfer contrast:

Is a method of increasing the contrast between tissues by physical rather than chemical means.

##### 7) MRElastography:

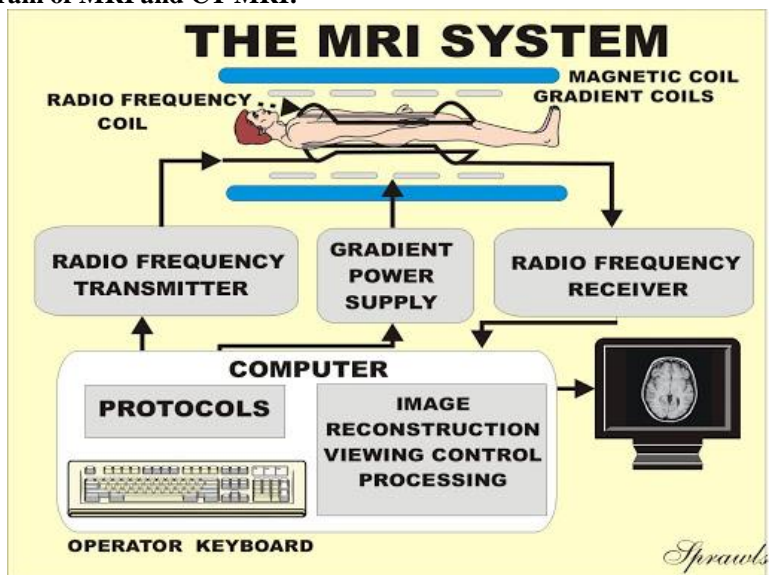
It is the imaging of shear waves using MRE Contrast in MRE is related to the elastic modulus of the tissue. MRI is recorded while ultrasound waves are being sent into the imaged volume. This technique is expected to find applications in locating pathology in soft tissue based on difference in the elastic modulus of tissues. Hence it is referred to as „magnetic resonance palpation“.

**8) Electron spin resonance (ESR) or electron paramagnetic resonance:**

ESR is based on the spin of with and rather than the nucleon. ESR imaging is the study of the spatial distribution of ESR signal bearing substance. Very few substances can be studied with ESR.

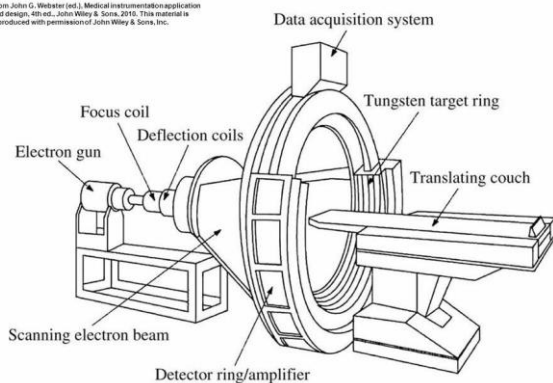
Nitroxide spin probes and some transition metals have an ESR signal. These substances have been studied directly by ESR, but are commonly used to probe biologic process with ESR. (11,12)

**Figure 1: Schematic Diagram of MRI and CT MRI:**

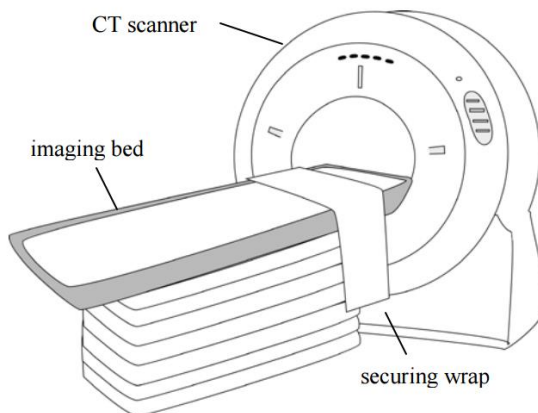


**CT:**

From John G. Webster (ed.), Medical instrumentation: application and design, 4th ed., John Wiley & Sons, 2010. The material is reproduced with permission of John Wiley & Sons, Inc.



**Figure 12.14** IMATRON electron beam CT system. (Courtesy of Doug Boyd, IMATRON Corp.)



**Computed tomography (CT):**

Since its inception in 1971, computed tomography (CT) has become a prolific diagnostic imaging tool, with over 70,000,000 exams performed annually in the United States (13). Indeed, there are numerous indications for performing CT-based exams, including evaluation of cerebrovascular disease, intracranial hemorrhage, sinusitis, pulmonary embolism, aortic dissection, fractures, and many tumors (14). The speed and accuracy with which CT can be obtained to diagnose many conditions largely

account for the desirability of this modality among ordering clinicians. However, there are drawbacks and limitations of CT, notably the exposure to ionizing radiation and the potential for misdiagnosis of certain diseases (15). Typical effective radiation doses in adults range from about 2 mSv (0.2 rad) for head CTs to about 8–10 mSv for CTs of the chest, abdomen, or pelvis. Although CT provides superior delineation of fine bony detail, magnetic resonance imaging (MRI) provides inherently better soft-tissue contrast than CT does. For example, MRI

with contrast is more sensitive than CT with contrast for the detection of brain metastases from small-cell lung cancer. The basic components of a standard diagnostic CT scanner include an X-ray source and a detector, positioned on opposite ends of the patient, mounted on a rotational gantry that can spin this imaging chain at very high speeds. A cross-sectional image is created by mathematical reconstruction of the measured X-ray intensities received by the detector at different positions around the patient in a circular orbit. Different tissues each have a different X-ray attenuation coefficient,  $\mu$ . The attenuation coefficients can be derived from the following equation (Beer–Lambert law):  $I = I_0 e^{-\mu x}$ , where  $I$  is the intensity of the detected X-ray,  $I_0$  is the intensity of the incident X-ray, and  $x$  is the thickness of the tissue that the X-ray beam traverses. The attenuation coefficients for different materials can be normalized with respect to the coefficient for water ( $\mu_w$ ), and the result is expressed in terms of Hounsfield units (HU):

$$HU = 1000 \times \frac{\mu - \mu_w}{\mu_w}$$

A CT image comprises a gray scale representation of the HU for each pixel, whereby each HU represents 0.1% of the attenuation of water. The HU, measured on the image by drawing regions of interest, provide insights into the nature of the tissues and lesions. Although the fundamental physical principles of CT imaging endure, many modifications have been introduced since the first clinical CT scanner (EMI Mark I) was developed in 1971.

The increased scope of clinical applications made possible by fast multidetector helical CT scanners has resulted in increased utilization of this modality, which has in turn heightened concerns regarding radiation dose to patients. Indeed, multidetector CT imparts a higher dose profile than single-detector CT, as much as 27% higher in the plane and 69% higher in the adjacent plane of the scanned area (16). Various strategies for decreasing radiation dose, such as increasing pitch and lowering tube current, have been implemented (17). In addition, automatic tube-current modulation systems have optimized image quality and decreased radiation exposure without arbitrary selection of tube current by operators (18). More recent innovations in CT technology have also resulted in better image quality, more widespread applications, and lower radiation doses. Notable advances reviewed in more detail in the following sections include extreme multidetector CT, iterative reconstruction algorithms, dual-energy CT (DECT), cone-beam CT (CBCT), portable CT, and phase-contrast CT.

Clinical Computed Tomography (CT) was introduced in 1971 - limited to axial imaging of the brain in neuroradiology. It developed into a versatile 3D whole body imaging modality for a wide range of applications in for example oncology, vascular radiology, cardiology, traumatology and interventional radiology. Computed tomography can be used for diagnosis and follow-up studies of patients, planning of radiotherapy treatment,

screening of healthy subpopulations with specific risk factors. Nowadays dedicated CT scanners are available for special clinical applications, such as for radiotherapy planning - these CT scanners offer an extra wide bore, allowing the CT scans to be made with a large field of view. The integration of CT scanners in multi modality imaging applications, for example by integration of a CT scanner with a PET scanner or a SPECT scanner. Other new achievements for dedicated diagnostic imaging new achievements concerns for example the development of a dual source CT scanner (a CT scanner that is equipped with two X-ray tubes), and a volumetric CT scanner (a 320 detector row CT scanner that allows for scanning entire organs within one rotation). CT scanning is perfectly suited for 3D imaging and used in, for example, brain, cardiac, musculoskeletal, and whole body CT imaging. The images can be presented as impressive colored 3D rendered images, but radiologists usually rely more on black and white, 2D images, being either the 2D axial images, or 2D reformats.

#### **CT Principle:**

The purpose of a computed tomography acquisition is to measure x ray transmission through a patient for a large number of views. Different views are achieved in computed tomography primarily by using detectors with hundreds of detector elements along the detector arc (generally 800-900 detector elements), by rotation of the x ray tube around the patient, taking about 1000 angular measurements and by tens or even hundreds of detector rows aligned next to each other along the axis of rotation. Beer's law only describes the attenuation of the primary beam and does not take into account the intensity of scattered radiation that is generated. For poly-energetic X ray beams Beer's law should strictly be integrated over all photon energies in the X ray spectrum. In the back projection methodologies developed for CT reconstruction algorithms, this is generally not implemented. Instead typically a pragmatic solution is to assume where Beer's law can be applied using one value representing the average photon energy of the X ray spectrum. This assumption causes inaccuracies in the reconstruction and leads to the beam hardening artefact. A CT image is composed of a matrix of pixels representing the average linear attenuation co-efficient in the associated volume elements (voxels) (19).

#### **CT Imaging System:**

After the pre-clinical research and development during the early 1970's, CT developed rapidly as an indispensable imaging modality in diagnostic radiology. Most of the modern CT technology that is being used in clinical practice nowadays was already described at the end of the year 1983. The CT gantry contains all devices that are required to record transmission profiles of a patient, since transmission profiles have to be recorded under

different angles these devices are mounted on a support that can be rotated (20).

**Conclusion:**

MRI is a complex but effective imaging system that has a variety of clinical indications directly related to the diagnosis and treatment of oral and maxillofacial abnormalities .While not routinely applicable in dentistry, appropriate use of MRI can enhance the quality of patient care in selected cases. Further advances in 3D imaging and dynamic scanning will enhance the use of this imaging technique even further.

In CT Patient related artefacts can sometimes be avoided by properly instructing the patient not to move during the scan and to maintain the breathhold during the entire scan, particularly during scans of the trunk. Movement of the heart and pulsation of the vessels cannot be avoided,acquisitions of, for example the coronary arteries or the aorta, therefore need to be optimized to achieve the best possible temporal resolution, pulsation of the aorta may induce artefacts that mimic an aortic dissection.

**REFERENCE:**

1. Revett K. An Introduction to Magnetic Resonance Imaging: From Image Acquisition to Clinical Diagnosis. Innovations in Intelligent Image Analysis 2011:127-61.
2. Ridgway JP. Cardiovascular magnetic resonance physics for clinicians: part I. J CardiovascMagnReson 2016;12:71.
3. Geva T. Magnetic resonance imaging: historical perspective. Journal of Cardiovascular Magnetic Resonance 2016;8(4):573-80.
4. Partain CL. The 2003 Nobel prize for MRI: Significance and impact. Journal of Magnetic Resonance Imaging 2004;19(5):515-26.
5. Andrews C, Simmons A, Williams S. Magnetic resonance imaging and spectroscopy Physics Education 1996;31:80.
6. Pekar JJ. A brief introduction to functional MRI. Engineering in Medicine and Biology Magazine, IEEE 2018;25(2):24-6.
7. Stehling MK, Turner R, Mansfield P. Echo-planar imaging: magnetic resonance imaging in a fraction of a second. Science 1991;254(43):5028-9.
8. Edzes HT, Van Dusschoten D, Van As H. Quantitative T2 imaging of plant tissues by means of multi-echo MRI microscopy. Magnetic Resonance Imaging1998;16(2):185-96.
9. Gore J. Out of the shadows MRI and the Nobel Prize. New England Journal of Medicine 2003; 349 (24):2290-2.
10. White SC, Pharoah MJ. Oral radiology: principles and interpretation. Mosby, St Louis 2000: 205-6.
11. Pruessmann KP, Weiger M, Scheidegger MB, Boesiger P. SENSE: sensitivity encoding for fast MRI. Magnetic Resonance in Medicine1999; 42 (5):952-62.
12. Gallez B, Bacic G, Goda F, Jiang J. Use of nitroxides for assessing perfusion,oxygenation, and viability of tissues: in vivo EPR and MRI studies. MagneticResonance in Medicine1996; 35 (1):97-106.
13. Am. Coll. Radiol. 2013. ACR Appropriateness CriteriaR . Guidelines, Reston, VA, updated Nov. 2013, accessed Nov. 10, 2013. <http://www.acr.org/Quality-Safety/Appropriateness-Criteria>
14. Berrington de Gonzalez A, Mahesh M, Kim KP, Bhargavan M, Lewis R, et al. 2009. Projected cancer ´ risks from computed tomographic scans performed in the United States in 2007. Arch. Intern. Med. 169:2071–77
15. Fred HL. 2004. Drawbacks and limitations of computed tomography: views from a medical educator. Tex. Heart Inst. J. 31(4):345–48
16. Thomton FJ, Paulson EK, Yoshizumi TT, Frush DP, Nelson RC. 2003. Single versus multi-detector row CT: comparison of radiation doses and dose profiles. Acad. Radiol. 10(4):379–85
17. Kalra MK, Maher MM, Toth TL, Hamberg LM, Blake MA, et al. 2004. Strategies for CT radiation dose optimization. Radiology 230:619–28
18. Kalra MK, Maher MM, Toth TL, Schmidt B, Westerman BL, et al. 2004. Techniques and applications of automatic tube current modulation for CT. Radiology 233:649–57
19. Buzug TM. Computed Tomography: From Photon Statistics to Modern Cone-Beam CT. ISBN 9783540394075. Springer. 2008.
20. Hsieh J. Computed Tomography: Principles, Design, Artifacts, and Recent Advances. SPIE Press Book. ISBN: 9780819475336. Second edition, 2009