



AWARENESS AND KNOWLEDGE REGARDING DIAGNOSTIC VARIABILITY AND ITS PRESENTATION IN AFEBRILE SEIZURE

¹Udhayan Felix*, ²Nithish Timothy, ³Rajalakshmi, ⁴Basheer, ⁵E.Prabhakar Reddy

¹Assistant Professor, Department of Radiodiagnosis, Melmaruvathur Adhiparasakthi Institute of Medical Sciences and Research Institute, Melmaruvathur, Tamilnadu, India.

²Senior Resident, Department of ENT, Sri Lakshmi Narayana Institute of Medical Science, (BIHER) Pondicherry, India.

³Assistant Professor, Department of Radiodiagnosis, Melmaruvathur Adhiparasakthi Institute of Medical Sciences and Research Institute, Melmaruvathur, Tamilnadu, India.

⁴Senior Resident, Department of Radiodiagnosis, Melmaruvathur Adhiparasakthi Institute of Medical Sciences and Research Institute, Melmaruvathur, Tamilnadu, India.

⁵Professor, Department of Biochemistry, Sri Lakshmi Narayana Institute of Medical Science, (BIHER), Pondicherry, India.

ABSTRACT

In a prospective observational study 50 children who were admitted with first afebrile seizure in department of pediatric Melmaruvathur Adhiparasakthi Institute of Medical Sciences and Research Institute, were underwent brain CT scan. Neuroimaging was performed (180/200) of these children within 48hours of their arrival to the Emergency Department. Seizures due to structural etiology, secondary to perinatal insult followed by metabolic and infections, are important causes. Imaging aids are important in etiological diagnosis. Etiological evaluation should be considered in children following first episode of afebrile seizures, especially in developing countries like India. This study would be useful in selecting patients for intensive investigations early in their clinical course for a possible surgical treatable cause; proper parental counseling and prevention of toxicity from an overdose of antiepileptic drugs and useless polytherapy can be minimized, in a country like India where a large treatment gap exists.

Key words: Seizure Disorder, Ring Enhancing Lesion Hypoxic Ischemic Encephalopathy, Structural, Abnormality.

INTRODUCTION

Seizure is the most common neurological illness in pediatric population and its risk is highest in the first year of life. Studies regarding etiology of afebrile seizures worldwide and in India are limited. Seizures are common pediatric neurological disorder. Four to 10% of children experience at least one episode of seizure in the first 16 years of their life. Incidence is highest in children less than 3 years of age, with a decreasing frequency from then on.[1] Seizures are a transient occurrence of signs and/or symptoms resulting from abnormal excessive or synchronous neuronal activity in the brain.[2] They account for 1% of all emergency department visits,[3]and

about 2% of visits of children's hospital emergency department visits. Worldwide, febrile seizures are the most common type of acute seizures in children.[4,5] Central nervous system (CNS) infections are the main cause of seizures and acquired epilepsy in the developing world.[5] Even after four decades of the initial studies on etiology and outcome of seizure in infants,[6] not much information is available on this aspect in India. This definition is very useful practically, as we can treat earlier, to prevent mortality and morbidity because of seizures, especially in developing countries like India. Information regarding

Corresponding Author :- **Dr. Udhayan Felix** Email:- udhayan_felix@yahoo.com

etiological profile of afebrile seizures is scarce, and there is paucity of data with the need for reaffirming awareness and knowledge regarding diagnostic variability and its presentations.

Common Cause Of Afebrile Seizure:-

Tuberculoma, Neurocysticercosis, calcified lesion Tumor, Infarct, Structural malformation of brain hypoglycemia, hypocalcemia.

Most common cause of afebrile seizure in India is NCC.

Inflammatory Granulomas:-

Inflammatory granulomas are an important cause of raised intracranial pressure and partial seizure in childhood. These may be tubercular, parasitic, fungal or bacterial in origin. NCC and Tuberculoma are commonest of granulomas.

Neurocysticercosis (NCC)-

It is caused by larva stage of *Taenia solium*.

NCC can be classified as Parenchymal, Intraventricular, Meningeal, Spinal cord, Ocular.

Clinical feature:

Parenchymal NCC – seizure are commonest manifestation (80%) followed by raised intracranial pressure focal deficits. seizure may be generalized or partial.

Tuberculoma:-

Intracranial tuberculoma is an important cause of space occupying lesion in both the developing and developed nations. In the paediatric population, tuberculomas account for 41 percent of intracranial lesions. Most frequent site of location in children was considered to be the cerebellum (in adults tuberculomas are supratentorial). Tuberculomas may be single or multiple.

CT Scan In tuberculoma:

Predictive value of computed tomography based diagnosis of intracranial tuberculomas. Studies have shown the sensitivity of CT in the diagnosis of intracranial tuberculoma as 100 percent and its specificity as 85.7%, the positive predictive value was only 33 percent (confidence limits 24 to 42%). The negative predictive value was 100%. The low positive predictive value for diagnosis of intracranial tuberculoma on CT alone indicates the need for a confirming histological diagnosis. Parietal lobe was the commonest site of single granuloma seen in 68% cases followed by frontal (20.9%), occipital (9.4%) and temporal lobe (1.7%).

Differential Diagnosis:

Cysticercus granuloma, Progenic abscess, Metastasis, Fungal granuloma, Glioma

Differentiation From Neurocysticercosis :

Single enhancing CT (NCC and tuberculoma) lesions are the commonest radiological abnormality in Indian patients with new onset partial seizures. Histopathological studies have proved that neurocysticercosis is the most common cause for these lesions.

Rajshekhar et al used CT features to differentiate between these two conditions after establishing definite diagnosis by stereotactic brain biopsy.

Brain Tumor:-

WHO classification of tumours of CNS and meninges 5 categories constitute 86% of all paediatric brain tumours – Juvenile pilocytic astrocytoma, medulloblastoma/ PNET, diffuse astrocytoma, ependymoma and craniopharyngioma. Childhood brain tumour reported a slight predominance of infratentorial tumour location 43.2% followed by supratentorial tumour location 40.9%, spinal cord 4.9%, age related difference in primary location of tumour with in first year of life – supratentorial tumour predominant. From 1-10 year age infratentorial tumour predominate

Brain Imaging :

Almost all patients with new-onset seizures should have a brain imaging study to determine whether there is an underlying structural abnormality that is responsible. MRI has been shown to be superior to CT for the detection of cerebral lesions associated with epilepsy. The purpose of performing a neuroimaging study in a child with first afebrile seizure is to detect a serious condition that may require immediate intervention. Guidelines for obtaining emergent neuroimaging in adult patients presenting with seizures have recently been published. It is recommended that emergent brain computed tomography (CT) scan should be performed for most adults with a new-onset seizure.

Our aim is to determine the prevalence of Neuro Imaging abnormality in Children (1 month to 14 years) with afebrile seizure and to collect evidence sufficient to make a recommendation for the use of routine neuroimaging in children with first episode of afebrile seizure.

Material & Methods

In this study 100 children aged between one month and 14 years with a new-onset afebrile seizure, admitted to the Paediatric Ward Melmaruvathur Adhiparasakthi Institute of Medical Sciences and Research Institute, Melmaruvathur, were respectively enrolled. We defined the first seizure using the International League against Epilepsy (ILAE) criteria to include multiple seizures within 24 hours, with recovery of consciousness between seizures. Patients with their afebrile seizure and absence of any laboratory abnormalities were entered into the study. Children who were previously diagnosed as neurological diseases, which were seriously ill to undergo

a neuroimaging procedure or whose parents were not willing to give consent were excluded from the study.

Data:

Included patient's age, sex, and the presence of any predisposing conditions, generalized or focal type of seizure, temperature, focal neurologic signs, Glasgow coma scale and any other abnormal findings in the neurologic examination. Laboratory investigations are

serum electrolytes, calcium, magnesium , and blood sugar, mantoux test. CT scans were performed within 48hours of arrival to hospital. All the emergent neuroimaging studies were conducted with and without the injection of contrast medium. Statistical analyses were conducted using SPSS software-11.5version. Variables were reported as mean ± SD. *P* value of <0.05 was considered statistically significant.

Table 1. Neuroimaging abnormalities of studied cases

Neuroimaging	No. of Cases	95% CI
Normal	30(33.3%)	22.81-43.24
Abnormal	60(66.7%)	51.38-83.86

Table 2. Neuroimaging Abnormalities

Neuroimaging Report	Frequency	Percent
Normal	30	33.3
NCC	25	27.7
Tuberculoma	15	16.6
Infract	04	4.4
Tumor	06	6.6
Misc.	10	11.1
Total	90	100

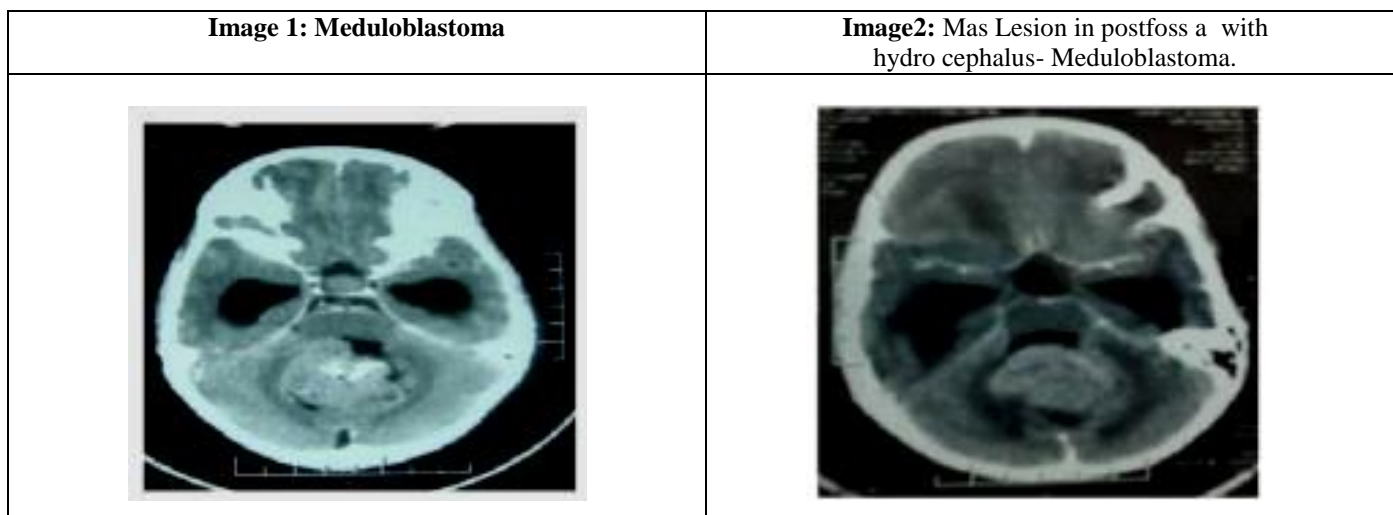
Table 3. Correlation Between Type of Seizure and Abnormal Neuroimaging

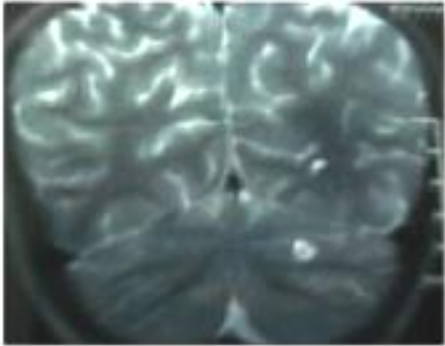
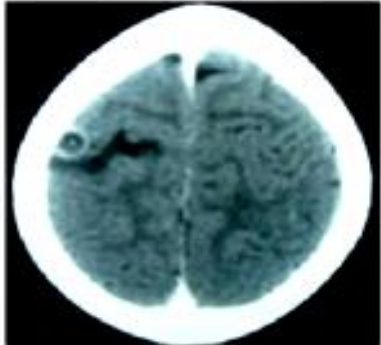
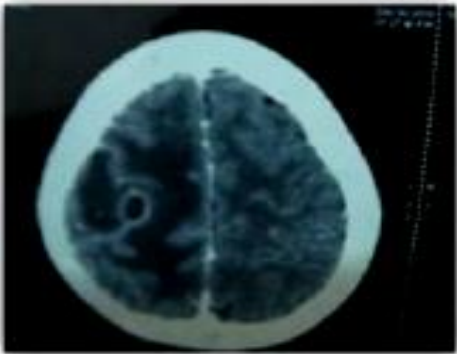
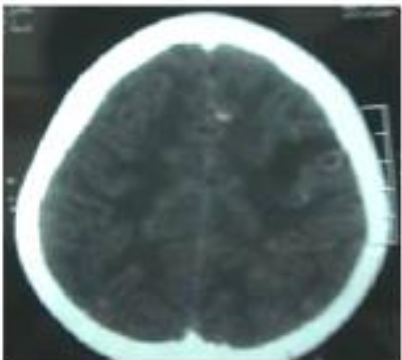
Neuroimaging	Seizure		
	Focal	General	Total
Abnormal	45 (81.8%)	15 (42.8%)	60 (66.6%)
Normal	10 (18.1%)	20 (57.1%)	30 (33.3%)
Total	55	35	90 (100%)

Table 4. Correlation Between Neurological Examination (GCS) and Neuro-imaging Report.

Neuro-imaging	GCS (< 9)	GCS (> 9)	Total No. of cases
Normal	06 (20%)	24 (80%)	30
Abnormal	10 (20%)	50 (80%)	60

$c' = 0.291, p > 0.05$ (Not significant)



<p>Image.3: MRI Vasicular stage in cerebellum</p> 	<p>Image 4 –Right flonter inflammatory granuloma</p> 
<p>Image 5:Tuberculoma</p> 	<p>Image 6 :Inflammatory granuloma with edema</p> 

Discussion:

Seizure disorder affects 50 million people worldwide & 80% of them belonged to developing countries.[7-8] Children are of no exception. Though Febrile seizure is the most common cause of seizure in children, it may be associated with grave diseases like infection, structural abnormalities of brain etc. Apart from febrile seizure birth asphyxia, metabolic cause, structural abnormalities of brain are important causes of seizure. [9-11] In previous study we found that seizure disorder is more common among male children [11]. As a result, a recommendation has been published to perform emergent neuroimaging in large population of adults having their first seizure.[11] So far, several studies have reported the prevalence of abnormal neuroimaging in children with new-onset seizures. The prevalence of abnormal neuroimaging in these studies ranged between 0 – 21% [12]. The proportion of children with febrile seizures ranged between 17% and [13]. It is important to note that children with febrile seizures, either simple or complex, are at low risk of neuroimaging abnormalities. Previous studies febrile seizures were an independent factor for intractable seizures. The association between febrile seizures and seizure intractability is controversial[13]. Major clinical features in our study were fever, altered sensorium & vomiting. Sarvanan S et al also noted in some studies [14]

Our study enrolled 162 patients with their first a febrile seizure. All patients with simple or complex febrile seizures, as well as those with recurrent seizures were excluded. Neuroimaging was performed in 90 patients and abnormalities were found in 66.7% of cases. The results showed that there was a significant relationship ($P < 0.001$) between focality of the seizure and abnormal neuroimaging. Febrile seizures were an independent factor for intractable seizures. The association between febrile seizures and seizure intractability is controversial. Result of our study shows a considerably higher proportion of neuroimaging abnormalities which includes various finding such as NCC, Tuberculoma, infract, tumor, misc. Adhikari S et al & Srestha S et al [15-16] found that NCC was the leading neuro-imaging features of children with seizure disorder. Contrary to them we found normal CT/MRI is more common among patient with seizure disorder. Though among abnormal CT/MRI ring enhancing lesion is most common cause of partial seizure but hypoxic ischemic encephalopathic changes are most common among children with GTCS. Thus our results shows a higher prevalence of neuroimaging abnormalities . Most common neuroimaging abnormality observed was NCC (40%) followed by tuberculoma(26%) that is similar to other study [15-16]. In our study various confounding factors may have direct correlation with abnormal

neuroimaging finding which includes low socioeconomic status, lower literacy rate, poor hygiene and poor nutritional status and higher prevalence of tuberculosis. The main limitations of this study are that it is a cross-sectional study and excludes neonate. These may alter the findings of this study significantly. But this study is able to give significant information regarding demographic profile of children with seizure disorder in rural area.

In our study 50% cases of generalized seizure and 83.8% cases of partial seizure have abnormal neuroimaging. Neuro-imaging emerged as an important modality of diagnosing seizure disorder now a days. Common associated clinical features with GTCS were fever, alteration of sensorium & vomiting. On the other hand, movement disorder, alteration of sensorium & focal neurological signs were more prevalent among children with partial seizure. Our study shows no significant association between neuro imaging abnormalities and abnormal neurological examination. Our result was not comparable due to higher proportion of NCC and tuberculoma cases presenting with normal neurological examination at the time of admission. Our study shows that mantoux positivity in CNS tuberculoma was 30.7% and history of contact was found in 38.4% cases. statistical

significance observed between mantoux positivity and tuberculoma ($P < 0.05$). In our study Parietal lobe was commonest site for inflammatory granuloma followed by frontal lobe. Based on our findings, we recommend that neuro imaging should be performed in children with their first a febrile seizure in area having high prevalence of NCC, tuberculosis.

This study would be useful in selecting patients for intensive investigations early in their clinical course for a possible surgical treatable cause; proper parental counseling and prevention of toxicity from an overdose of antiepileptic drugs and useless polytherapy can be minimized, in a country like India where a large treatment gap exists.

Conclusion:-

This study may further help to form treatment protocol of seizure disorder. But further studies preferably multicentric will have to be conducted for better information. Incidence of neuro-imaging abnormality in children presenting with first afebrile seizure is high in developing countries like India due to high prevalence of NCC and tuberculosis so neuro-imaging should be considered in any child with first afebrile seizure.

References:

1. Friedman MJ, Sharieff GQ. Seizures in children. *Pediatr Clin North Am.* 2006;53:257–77.
2. Kleigman RM, Stanton BM, St. Geme J, Schor NF, Behrman RE. *Nelson textbook of pediatrics.* 20th ed. Philadelphia (PA): Elsevier Saunders; 2015. Seizures in childhood; p. 2823
3. Martindale JL, Goldstein JN, Pallin DJ. Emergency department seizure epidemiology. *Emerg Med Clin North Am.* 2011;29:15–27.
4. Hauser WA. The prevalence and incidence of convulsive disorders in children. *Epilepsia.* 1994;35:S1–6
5. Idro R, Gwer S, Kahindi M, Gatakaa H, Kazungu T, Ndiritu M, et al. The incidence, aetiology and outcome of acute seizures in children admitted to a rural Kenyan district hospital. *BMC Pediatr.* 2008;8:5.
6. Chevrie JJ, Aicardi J. Convulsive disorders in the first year of life: Etiologic factors. *Epilepsia.* 1977;18:489–98.
7. Vining EP. Pediatric seizures. *Emergency Medicine Clinics of North America.* 1994; 12: 973–88. 2. Singhi P, Singhi S. Neurocysticercosis in children. *Indian Journal of Pediatrics.* 2009; 76: 537–45.
8. McAbee GN, Wark JE. A practical approach to uncomplicated seizures in children. *American family Physician.* 2000;62 :1109–16.
9. Rajbhandari KC. Epilepsy in Nepal. *Canadian Journal of Neurological Sciences.* 2000;31: 257–60.
10. Stafstrom CE. Neonatal seizures. *Pediatrics in Review.* 1995;16:248–56.
11. No authors listed. Practice parameter: neuroimaging in the emergency patient presenting with seizure (summary statement). American College of Emergency Physicians, American Academy of Neurology, American Association of Neurological Surgeons, American Society of Neuroradiology. *Ann Emerg Med.* 1996; 28: 114 – 118.
12. Landfish N, Gieon-Korthals M, Weibley RE, Panzarino V. New onset childhood seizures. Emergency department experience. *J Fla Med Assoc.* 1992; 79: 679 – 700.
13. Sujit Sharma, James J. Riviello, Marvin B. Harper, and Marc N. Baskin: The Role of Emergent Neuroimaging in Children With New-Onset Afebrile Seizures official journal of the American Academy of Pediatrics 111;1, 2003
14. Saravanan S. Profile of children admitted with seizures in a tertiary care hospital in South India. *IOSR Journal of Dental and Medical Sciences.* 2013; 4: 56–61.
15. Adhikari S, Sathian B, Koirala DP, Rao KS: Profile of children admitted with seizures in a tertiary care hospital of Western Nepal. *BMC Pediatrics.* 2013;13:1.
16. Shrestha BM. Childhood neurocysticercosis: clinico-radiological profile and outcome. *Journal of Nepal Paediatric Society.* 2008; 28:14–16.